J HK Coll Radiol 2002;5:105-108

CASE REPORT

Idiopathic Spinal Epidural Lipomatosis

RKT Lee,[1] LF Chau,[1] KS Yu,[2] CW Lai[1]

[1]Department of Radiology, North District Hospital, [2]Department of Orthopaedics & Traumatology, North District Hospital, Hong Kong

ABSTRACT

Spinal epidural lipomatosis is most often associated with exogenous steroid therapy and endocrinopathy. Idiopathic spinal epidural lipomatosis is a rare disease. Obesity may be associated with this condition. We report the case of a patient with persistent back pain after an accidental fall from height. Excessive fat deposition was found in the lumbar spinal canal on magnetic resonance imaging. Other possible causes of back pain, including spondylolysis with nerve root impingement and prolapsed intervertebral discs were excluded by injection tests and discograms. Clinical and pathologic features of idiopathic spinal epidural lipomatosis, along with treatment options are discussed.

Key words: *Lipomatosis, Magnetic resonance imaging, Obesity*

INTRODUCTION

Spinal epidural lipomatosis refers to pathological adipose tissue overgrowth in the vertebral canal. The excessive epidural fat usually occurs in the thoracic and lumbar spine. It is most often associated with exogenous steroid therapy, and endocrinopathies, such as Cushing's syndrome. Idiopathic spinal epidural lipomatosis is a rare disease.

We report the case of a 34-year-old patient who presented with persistent back pain following an industrial injury. Spinal epidural lipomatosis was identified on MRI of the lumbar spine.

CASE REPORT

A 34-year-old man sustained an industrial injury, falling from a height of approximately 3 metres and landing on his buttocks. He complained of neck pain, left wrist pain, back pain, and left hip pain. Physical examination showed no neurological deficit or sphincter dysfunction. There was some decrease in left lower limb power (grade $3^+/5$) noted, mainly due to pain. Plain radiographs showed fracture of the left inferior pubic ramus. The patient was treated conservatively with rest, analgesics, and physiotherapy, with improvement seen with respect to both pain and left lower limb power. Persistent back pain was reported after six months despite conservative treatment, however. MRI performed at a private facility showed excessive fat deposition at the L4 and L5 level of the spinal canal within the anterior and posterior epidural space. The deposition measured approximately 9 mm in sagittal thickness. The dural sac was compressed by the epidural fat, and had a typical 'Y-shaped' configuration (Figure 1). Bilateral L5 spondylolysis was also evident.

The patient did not have a history of Cushing's disease or long-term steroid intake. Given the radiological diagnosis of spinal epidural lipomatosis, the patient was referred to the dietitian for weight reduction. The patient achieved a reduction in weight from 94.5 kg to 91.5 kg in the following three months, well below the target deemed clinically effective of at least 15 kg. No change in his symptoms was reported. A repeat MRI was performed, which showed a slight decrease in the epidural fat compared with the previous MRI study.

In view of the persistent symptoms, more invasive investigations were undertaken to exclude other causes of back pain. Lysis injection tests of the right and left L5 spondylolysis were performed (Figure 2). Insertion

Correspondence: *Dr. RKT Lee, Department of Radiology, North District Hospital, 9 Po Kin Road, Sheung Shui, New Territories, Hong Kong.*
Tel: (852) 2683 7378; Fax: (852) 2683 7379;
E-mail:leektr@netvigator.com

Submitted: 8 January 2002; Accepted: 19 February 2002.

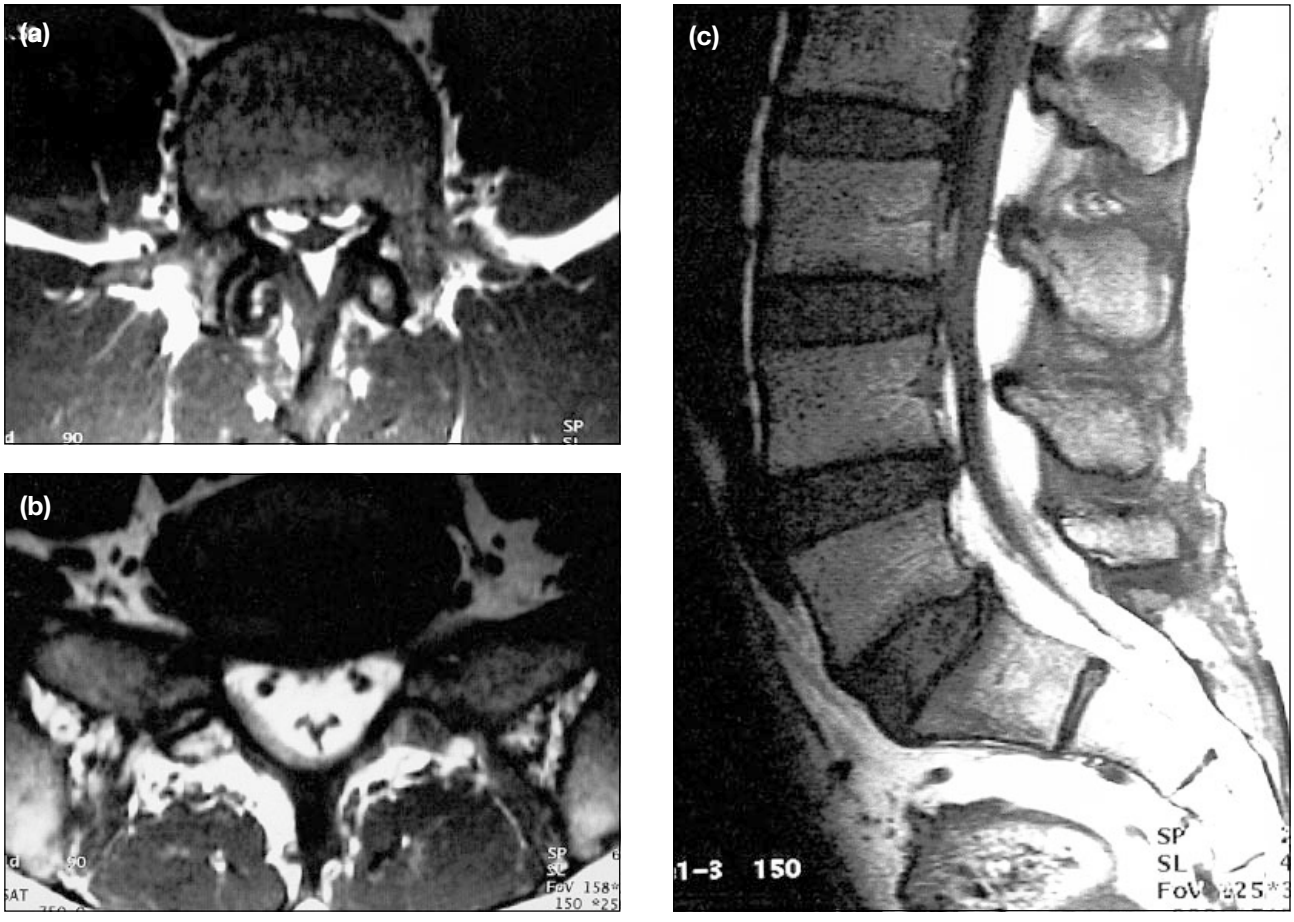

Figure 1. MRI studies show the presence of spinal epidural lipomatosis; (a) axial T1-weighted image at the L4 level demonstrates an increase in epidural fat, with a sagittal thickness of 9 mm; (b) axial T1-weighted image at the L5/S1 level illustrates the characteristic 'Y-sign' of the thecal sac seen in spinal epidural lipomatosis; (c) sagittal T1-weighted image of the lumbosacral spine shows an increase in epidural fat which is most obvious at the L4 to L5 levels.

of a coaxial needle (18G outer needle and 22G inner needle) into the lysis sites, together with injection of 1.5 mL marcaine, produced a 30% decrease in pain, which did not constitute a positive test result.[1] CT-guided discograms of the L4/5 and L5/S1 intervertebral discs (Figure 3) produced dissimilar pain, which was not related to the patient's symptoms.

After exclusion of other possible causes of back pain, it was concluded that the patient's persistent symptoms were most likely caused by the spinal epidural lipomatosis. Since the patient refused operative treatment, conservative treatment and weight-reduction continued.

DISCUSSION

Spinal epidural lipomatosis is an uncommon disease in which excess adipose tissue deposits around the thecal sac may cause back pain but rarely radicular impingement.[2] Symptomatic spinal epidural lipomatosis has rarely been reported in patients without a history of long-term steroid therapy or endocrinopathy, such as Cushing's syndrome or hypothyroidism.[3]

It has been suggested that idiopathic spinal epidural lipomatosis is associated with obesity, with the gradual overgrowth of epidural fat resulting in spinal cord and nerve root compression.[4] The identification and diagnosis of idiopathic epidural lipomatosis has increased over recent years. There are two possible explanations for this trend. Firstly, the obese population has increased over recent decades. United States statistics on obesity have shown an increase of at least 8% in the obese population since 1980, compared with a 1% increase from 1960 to 1980.[5] Secondly, increasing diagnosis of idiopathic epidural lipomatosis appears to correlate well with the advent of MRI.[6] The high contrast between adipose tissue and the thecal sac on T1-weighted MRI permits an accurate evaluation of the extent of pathologic epidural adipose tissue overgrowth in the spinal canal. This makes MRI the diagnostic imaging modality of choice for this condition.

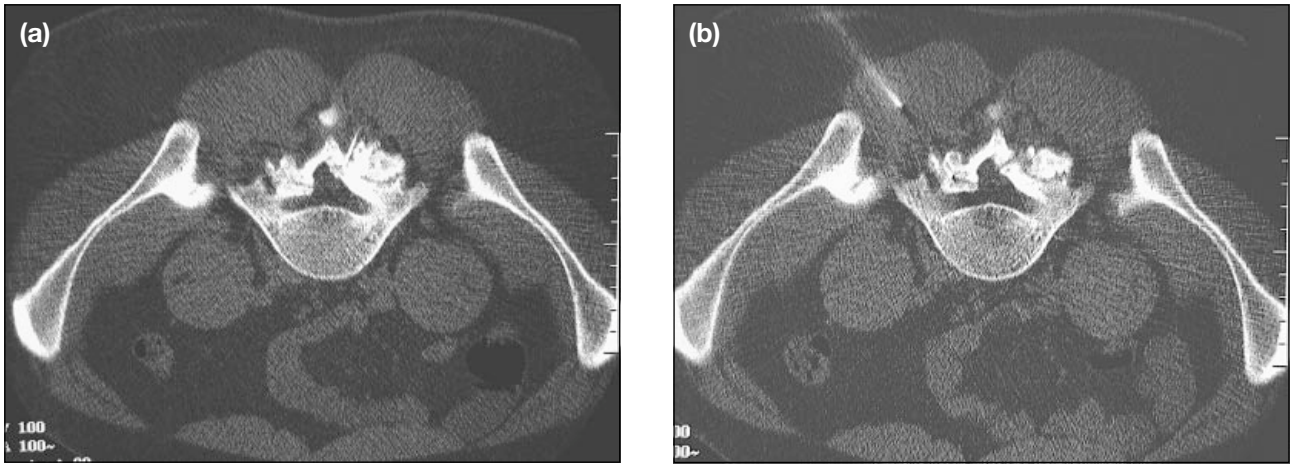

Figure 2. Lysis injection tests of the (a) right and (b) left L5/S1 spondylolysis performed under CT guidance, with the patient in prone position. Coaxial needles are used.

There seems to be a strong male preponderance in idiopathic spinal epidural lipomatosis.[3,6] The condition is most commonly found at T6-T8 levels of the thoracic spine and L4-L5 levels of the lumbosacral region. Patients with thoracic spinal epidural lipomatosis generally present at an earlier age than the lumbosacral group (average age 38.1 years versus 51.4 years). This might be explained by the narrower space of the thoracic spinal canal, limited vascularity, and the fact that a larger proportion of epidural fat offers very little compliance to compressive effects.[7]

Back pain radiating to the lower limbs is the most frequent initial symptom. The onset of symptoms is usually gradual. Some patients, however, may report a rather abrupt onset of complaints, and some particular movements or even an accidental fall may act as a trigger.[8] Weakness is the most frequent finding on neurological examination.

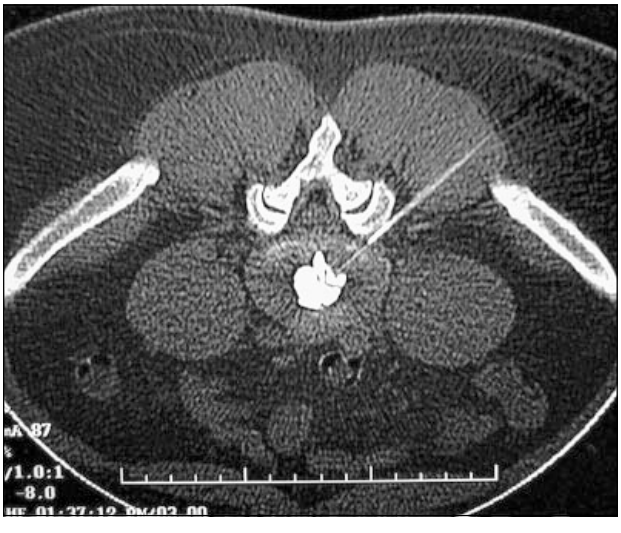

Figure 3. Discogram of the L4/5 intervertebral disc performed under CT guidance, with the patient in prone position. A coaxial needle is used. Grade 1 posterior annulus tear is demonstrated.

Spinal MRI is the diagnostic imaging modality of choice. On conventional spin echo MRI, fat demonstrates a high signal intensity on non-contrast T1-weighted images and an intermediate signal intensity on T2-weighted images. On axial MRI of the lumbar spine, the thecal sac can have a stellate appearance with three rays radiating from the central core. This configuration was described by Kuhn et al[9] as the 'Y-sign' of the thecal sac, a finding which is pathognomonic for lumbar epidural lipomatosis.[9] The normal range for sagittal epidural fat thickness is approximately 3 to 6 mm, while in symptomatic spinal epidural lipomatosis, the sagittal epidural fat thickness may reach up to 7 to 15 mm.[7,10] Spinal epidural lipomatosis should be differentiated from other extradural lesions. If a well-defined margin can be demonstrated, it tends to favour a focal lipomatous lesion such as lipoma. Conversely, a diffuse increase in the epidural fat suggests spinal epidural lipomatosis.[10]

There are two treatment options for idiopathic spinal epidural lipomatosis — surgical treatment by decompressive laminectomy and fat debulking, and conservative management with weight reduction.[3,11] The indication for surgical decompression is determined by the patient's neurological status. Delayed surgical treatment should be avoided because of the risk of progression of neurological deficits. Decompressive laminectomy is also indicated in cases of failure of conservative treatment. After debulking of the excess epidural fat, it is possible for the thecal sac to resume its normal configuration.[6] Patients with limited

neurological deficits can be treated conservatively by weight reduction. For weight reduction to be effective, a loss of 15 kg or more is necessary, however.[6]

CONCLUSION

Idiopathic spinal epidural lipomatosis is a rare condition in which there is excess fat deposition around the thecal sac. Obesity appears to have a contributory role in development of the disease. Onset of back pain is usually gradual, but may also be abrupt after trigger factors, such as an accidental fall. MRI is the imaging modality of choice for diagnosis and follow-up of the disease.

REFERENCES

1. Wu SS, Lee CH, Chen PQ. Operative repair of symptomatic spondylolysis following a positive response to diagnostic pars injection. J Spinal Disord 1999;12:10-16.
2. Lisai P, Doria C, Crissantu L, Meloni GB, Conti M, Achene A. Cauda equina syndrome secondary to idiopathic spinal epidural lipomatosis. Spine 2001;26:307-309.
3. Sato M. Yamashita K, Aoki Y, Hiroshima K. Idiopathic spinal epidural lipomatosis: a case report and review of literature. Clinical Orthop 1995;320:129-134.
4. Haddad SF, Hitchon PW, Godersky JC. Idiopathic and glucocorticoid-induced spinal epidural lipomatosis. J Neurosurg 1991; 74:38-42.
5. Kuczmarski RJ, Flegal KM, Campbell SM, Johnson CL. Increasing prevalence of overweight among US adults. JAMA 1994;272:205-211.
6. Robertson SC, Traynelis VC, Follett KA, Menezes AH. Idiopathic spinal epidural lipomatosis. Neurosurgery 1997;41:68-74.
7. Quint DJ, Boulos RS, Sanders WP, Mehta BA, Patel SC, Tiel RL. Epidural lipomatosis. Radiology 1988;169:485-490.
8. Hierholzer J, Benndorf G, Lehmann T, et al. Epidural lipomatosis: case report and literature review. Neuroradiology 1996;38: 343-348.
9. Kuhn MJ, Youseff HT, Swan TL, Swenson LC. Lumbar epidural lipomatosis: The “Y” sign of thecal sac compression. Comput Med Imaging Graph 1994;18:367-372.
10. Kumar K, Nath RK, Nair CPV, Tchang SP. Symptomatic epidural lipomatosis secondary to obesity. J Neurosurg 1996;85: 348-350.
11. Kurt E, Bakker-Niezen SH. Neurogenic claudication by epidural lipomatosis: a case report and review of literature. Clinical Neurol Neurosurg 1995;97:354-357.